

CASE REPORT

Anny Sauvageau,¹ M.D., M.Sc.; Stéphanie Racette¹; and Rose Yesovitch,¹ B.Sc., M.F.S.

Suicide by Inhalation of Carbon Monoxide in a Residential Fire

ABSTRACT: Fire deaths are usually accidental, but atypical cases of homicide or suicide have been described. In suicide by fire, the only method reported by several authors consists of self-immolation. We present here the unusual case of an adult female who committed suicide by waiting in the living room after setting fire to her bedroom. The autopsy revealed smoke inhalation and the toxicological analysis revealed carboxyhemoglobin levels of 67%. Very few cases of suicide by fire not of the self-immolation type have been reported, and all have been anecdotal. A review of the literature is presented and a new term, "suicide by inhalation of carbon monoxide in a fire," is proposed for such cases.

KEYWORDS: forensic science, death investigation, suicide, fire, carbon monoxide

Deaths by fire are, for the most part, accidental. However, when the fire is deliberately set, the case may be classified as a homicide. Suicide by this method is so unusual that it is not listed in the possible manners of death by fire according to DiMaio (1), and is not listed in most official statistics (2).

Self-immolation is the only form of suicide by fire that has been reported in the literature (3–6). This method, also known as self-incineration, is defined as the act of pouring a flammable liquid, generally gasoline, onto oneself and setting it on fire (7). It is observed in three victim populations: those with psychiatric problems, personal reasons, or political motivations (8).

A Miami study dating from 1977 to 1984 found 24 cases of suicide by self-immolation, representing 0.96% of suicides (4). Thirty-two deaths by self-immolation were reported in a Canadian study from 1986 to 1988, representing 1% of suicides (6). A thorough literature review from 1965 to 1994 by Geller (9) revealed 582 cases in a total of 27 studies. A more recent 20-year review from 1982 to 2002 examined 55 studies for a total of 2296 suicidal fire deaths (8).

There appears to be a cultural difference in the frequency of suicide by fire. Self-immolation is much more frequent in Asia than in the Western world. India shows the highest number of cases, although the highest incidence is in Sri Lanka (8). What follows is the case report of a suicide by inhalation of carbon monoxide in a residential fire.

The Fire Scene

A 49-year-old woman was found sitting on a chair in the living room of her home where a fire had been set in one of the bedrooms (Fig. 1). The doors of the house were locked and there was no

evidence that the victim had tried to escape the fire. It was reported that on the day of her death, the victim's husband left for work at approximately 6:40 am. The woman was apparently awake in the living room at that time. At about 7:01 am, flames and smoke were seen at the residence.

The woman had suffered from a major depressive episode about two years earlier. It appears that she had recently suffered a relapse, and had expressed self-destructive intentions in the days leading up to her death.

The investigation revealed that the fire had originated from cardboard boxes containing papers in the closet of the master bedroom. It was also proved by the pattern of soot on the doorframes that the door of this room was open during the fire (Fig. 2). The analysis showed that the fire had been intentionally lit using gasoline. A gas can was found in the house. There was no evidence of a suicide note.

Autopsy Findings

The autopsy revealed an obese Caucasian female, measuring 1.48 m (4 ft 10½ in) in height and weighing 74.09 kg (163 lb). Livor mortis was bright pink and compatible with the sitting position previously described. Soot deposits were observed on the anterior part of the body, more precisely on the face, hands, arms, upper thorax and the dorsal surfaces of the feet (Fig. 6). The upper limbs and the anterior trunk and thighs showed 1st and 2nd degree burns. On internal examination, soot was found in the nostrils, mouth, larynx, oesophagus, trachea, bronchi and lungs. The organs were bright pink and the blood was cherry-red. Aside from minor burns, no significant traumatic lesions were found. There was no cardiovascular pathology or other physical disease to account for death.

The toxicological analysis revealed a lethal blood concentration of carboxyhemoglobin (67%), confirming that the woman was alive when exposed to the fire (the determination of carboxyhemoglobin in the victim's blood was realised according to the Katsumata method) (10). Alcohol and drugs tests were negative,

¹ Laboratoire de sciences judiciaires et de médecine légale, Edifice Wilfrid-Derome, 1701, Parthenais street, 12th floor, Montreal (Quebec) Canada, H2K 3S7.

Received 30 Nov. 2004; and in revised form 18 Feb. 2005; accepted 27 Feb. 2005; published 25 May 2005.

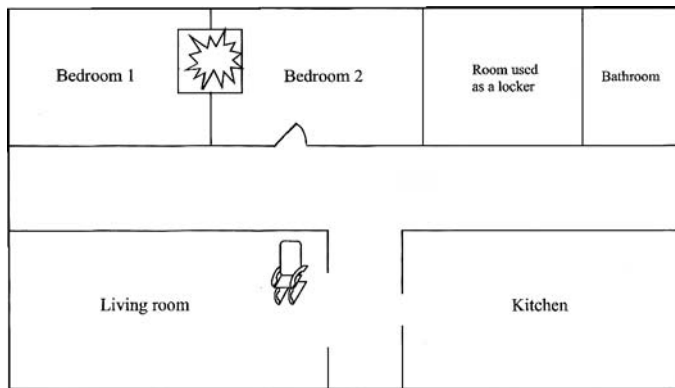


FIG. 1—Graphic reconstruction of the first floor—Position of the rocking chair and the fire origin.



FIG. 2—View of the door leading to the master bedroom—Soot deposit on both side of the doorframe suggesting that the door was open during the fire.

except for traces of sertraline. Death was attributed to asphyxia associated with carbon monoxide intoxication during a fire.

Discussion

After having considered all of the investigation's elements including the fire scene and autopsy findings, it was determined that the manner of death was suicide. Some may object to this conclusion due to the absence of a suicide note; however, it is consistent with the corresponding literature. Studies on self-immolation have shown that a suicide note is rarely found in suicide by fire (4,6,7,11).

The present case of suicide by fire is very unusual because it does not involve self-immolation. In fact, very few cases such as this have been reported, and all have been anecdotal. There is a reported case of forced double suicide by fire (12) where a father set a fire with gasoline, burning his son to death (immolation type), and then died in the fire himself after ingestion of Endrin, an organochlorine insecticide. The father's death was a suicide by fire not of the self-immolation type, but associated with intoxication with Endrin. Toxicological analysis revealed a carboxyhemoglobin concentration greater than 90% in the left ventricular blood and the presence of Endrin in the stomach contents. Another case of suicide using a combined method including fire is described by Tatsumi (13). The case describes a man hanging himself with an electric cord in a room that had been previously set on fire. Before

hanging himself, the man poured gasoline in the room and ignited it with a lighter. A case particularly similar to ours is that of a 48-year-old man discovered partially burned upon the remains of a living room chair, next to the wall separating the bedroom from the living room (3). The fire had originated from the bedroom, and had been deliberately set with the aid of accelerants. At autopsy, active smoke inhalation and a 15% concentration of carboxyhemoglobin were noted. The case was ruled a suicide and a suicide note was found at the scene, supporting this conclusion. Finally, three cases of suicide by smoldering fire are briefly mentioned in a study by Rodge and Olving (14).

Non-immolation suicides by fire are rare and important to distinguish from the typical immolation type. Unfortunately, the authors could not find an existing designation for these cases in the literature. Therefore, it is proposed that the term "suicide by inhalation of carbon monoxide in a fire" be used. This appellation would be useful to differentiate similar cases, as well as to create a classification for future possible studies on the subject.

Acknowledgments

The authors gratefully thank Mr Ronald Coulombe and Mrs Carole Rousseau for their precious advice. The authors would also like to thank Mr Pierre-Paul Lantin for the crime scene photos and Mr Thierry Marcoux for the image preparation.

References

- DiMaio VJ, DiMaio D. Fire deaths. In: Geberth VJ, series editor. Forensic pathology. 2nd ed. Boca Raton, FL: CRC Press, 2001;367–87.
- Maltsberger JT, Varnik A, Maris R. [Laur's final display: suicide by fire.](#) *Suicide Life Threat Behav* 2003 Winter;33(4):448–51. [PubMed]
- Davis JH. Suicide by fire. *J Forensic Sci* 1962;7:393–7.
- Copeland AR. Suicidal deaths revisited. *Z Rechtsmed* 1985;95:51–7. [PubMed]
- Meir PB, Sagi A, Ben Yakar Y, Rosenberg L. Suicide attempts by self-immolation—our experience. *Burns* 1990;16:257–8. [PubMed]
- Shkrum MJ, Johnston KA. Fire and suicide: a three year study of self-immolation deaths. *JFSCA* 1992;37:208–21.
- Leth P, Hart-Madsen M. [Suicide by self-incineration.](#) *Am J Forensic Med Pathol* 1997;18(2):113–8. [PubMed]
- Laloë V. [Patterns of deliberate self-burning in various parts of the world: a review.](#) *Burns* 2004 May;30:207–15. [PubMed]
- Geller JL. [Self-incineration: a review of the psychopathology of setting oneself afire.](#) *Int J Law Psychiatry* 1997;20:355–72.
- Katsumata Y, Aoki M, Sato K, Oya M, Yada S, Suzuki O. [A simple spectrophotometric method for the determination of carboxyhemoglobin in blood.](#) *Forensic Sci Int* 1981 Sep–Oct;18(2):175–9. [PubMed]
- Ashton JR, Donnan SP. Suicide by burning—a current epidemic. *Br Med J* 1979;2:769–70. [PubMed]
- Kinoshita H, Ijiri I, Ameno S, Fuke C, Tanaka N, Kubota T et al. Forced double suicide by fire revealed by autopsy and toxicological examination: a case report. *Nippon Hoigaku Zasshi* 1997 Dec;51(6):457–61. [PubMed]
- Tatsumi S, Noda H, Sugiyama S. An autopsy case of a charred body which committed suicide after arson. *Leg Med (Tokyo)* 2000 Aug;2(2):110–4. [PubMed]
- Rodge S, Olving JH. [Characteristics of fire victims in different sorts of fires.](#) *J Forensic Sci* 1996;77:93–9.

Additional information and reprint requests:

Anny Sauvageau, M.D., M.Sc.
 Laboratoire de sciences judiciaires et de médecine légale
 Édifice Wilfrid-Derome
 1701, Parthenais street, 12th floor
 Montreal (Quebec) Canada
 H2K 3S7
 Tel: (514) 873-3300
 Fax: (514) 873-4847
 E-mail: a.sauvageau@mssp.gouv.qc.ca